

# Peritonectomy Treatment for Recurrent Sclerosing Encapsulated Peritonitis Attacks: Case Report

## Tekrarlayan Sklerozan Enkapsüle Peritonit Ataklarında Peritonektomi Tedavisi

Eyüp Murat YILMAZ,<sup>a</sup>  
Cem AYDOĞAN,<sup>a</sup>  
Zafer ÖNER<sup>b</sup>

<sup>a</sup>Department of General Surgery,  
Başkent University Faculty of Medicine,

<sup>b</sup>Department of General Surgery,  
Hacettepe University Faculty of Medicine,  
Ankara

Geliş Tarihi/Received: 11.04.2016  
Kabul Tarihi/Accepted: 26.09.2016

Yazışma Adresi/Correspondence:  
Eyüp Murat YILMAZ  
Başkent University Faculty of Medicine,  
Department of General Surgery, Ankara,  
TÜRKİYE/TURKEY  
drmyilmaz80@gmail.com,

**ABSTRACT** Encapsulated sclerosing peritonitis is a rare small bowel obstruction statement and usually has nonspecific clinical situations and radiological findings. It is mainly diagnosed intraoperatively. Although many reasons are found to be suspicious in etiology, it is mostly caused by exposure to the peritoneal dialysis. It usually responds to surgical treatment and peritonectomy which is an exhausting choice is the best treatment option. In this report, we will present a 53-year-old case having peritonectomy admitted with recurrent sclerosing encapsulated peritonitis attacks.

**Key Words:** Peritonitis; peritoneal dialysis; surgical procedures, operative

**ÖZET** Enkapsüle sklerozan peritonit, genellikle nonspesifik klinik ve radyolojik bulgularla seyreden ve nadir ince barsak obstrüksiyonu yapan bir durumdur. Ana tanı intraoperatif olarak konur. Etiyolojide birçok sebep suçlanmasına rağmen, en sık sebep peritoneal diyalize sık maruz kalmak olarak görülmüştür. Genellikle cerrahi tedavi ve peritonektomi en iyi tedavi seçeneğidir. Bu yazımızda, tekrarlayan enkapsüle sklerozan peritonit atakları olan 53 yaşındaki, peritonektomi yaptığımız bir olgumuzu sunacağız.

**Anahtar Kelimeler:** Peritonit; periton diyalizi; cerrahi işlemler, operasyon

**Türkiye Klinikleri J Case Rep 2016;24(4):362-4**

Encapsulated sclerosing peritonitis, characterized by a statement in which the small bowels are completely wrapped with a fibrous membrane, is a rare small bowel obstruction statement.<sup>1-3</sup> Obstructions can be partial or full and this statement can repeat as attacks.<sup>4</sup> Patients often apply to clinic with obstruction symptoms such as abdominal pain, nausea, and vomiting and their radiological findings are usually nonspecific.<sup>5</sup> We will present, in this report, our case who had undergone peritoneal dialysis due to chronic renal failure for 10 years and then was operated for recurrent attacks of sclerosing encapsulated peritonitis.

### CASE REPORT

Fifty-three-year-old female patient, was diagnosed with chronic kidney failure 11 years ago and began to undergo peritoneal dialysis. She had bilateral nephrectomy 5 years ago. About 2 years ago when the case applied to an another hospital with complaints of abdominal pain, nausea and vom-

doi: 10.5336/caserep.2016-51726

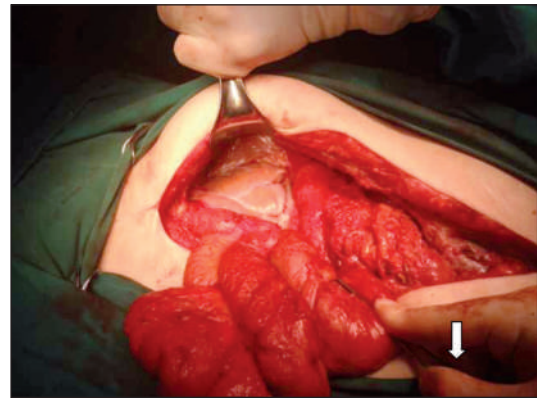
Copyright © 2016 by Türkiye Klinikleri

iting, she was operated with early diagnosis of ileus, and upon detection of sclerosing encapsulated peritonitis the patient underwent bridectomy and peritonectomy. After pathology report confirmed sclerosing peritonitis, the peritoneal dialysis was terminated and hemodialysis treatment began. Later, after having same attacks 2 more times the patient underwent laparotomy in external centers and was operated. The patient, saying that she spent the last 2 years comfortable, was admitted to our emergency service after having nausea, vomiting and abdominal pain for a week. Laboratory values were found to be normal in blood tests conducted subsequently.

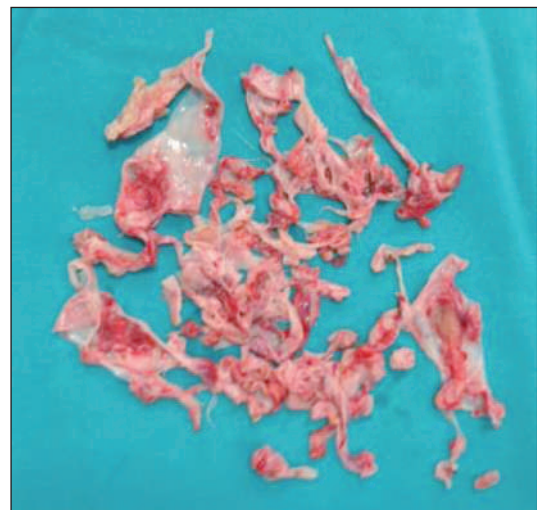
In the abdomen tomography, dilatation in the proximal jejunum and the duodenum of the small bowel, free liquid and widespread adhesions due to the surgical operations were detected. Providing information about her status consents were obtained and the patient underwent a surgery. There were extensive adhesions due to previous operation. The abdomen was opened and bridectomy was performed. Encapsulated peritoneal fibrosis, completely wrapping over small intestine, was observed (Figure 1). Visceral peritonectomy was performed and bowels were completely released (Figure 2). Meanwhile, 3 injury parts were seen in a small intestine loop of 100 cm and each was resected. End to end anastomosis was performed. The patient was discharged on postoperative 5<sup>th</sup> day and no problem was observed in her follow-ups.

## DISCUSSION

Sclerosing encapsulated peritonitis, defined for the first time in the world by Owtschinnikow in 1907, is divided into two types as idiopathic and secondary.<sup>3</sup> The most common cause of secondary ones has been reported to be due to peritoneal dialysis.<sup>6</sup> Apart from this, reasons such as several surgeries, liver transplantation, sarcoidosis, tuberculosis and ventriculoperitoneal peritoneal shunt are among the risk factors.<sup>7</sup> Our patient had also risk factors as known history of 5 laparotomies and peritoneal dialysis history of for almost 10 years. While peritoneal dialysis is a comfortable treatment option for end-stage renal failure patients, continuous use and



**FIGURE 1:** Encapsulated peritoneal fibrosis (All small intestine was wrapped).



**FIGURE 2:** After peritonectomy.

irregular care can cause risk of contamination and bacterial translocation and subsequently 0.9-7.3% risk of sclerosing encapsulated peritonitis.<sup>8</sup>

The clinic of sclerosing encapsulated peritonitis, according to the classification made by Kawashishi et al., is divided into four phases: peritonitis phase, inflammatory phase, progressive phase, and fibrotic phase.<sup>9</sup> Symptoms are generally nonspecific obstruction symptoms (nausea, vomiting, abdominal pain), and patients are often admitted to the hospital in peritonitis phase or inflammatory phase. Our case was in 4<sup>th</sup> attack and in fibrotic phase. Radiologic findings are usually nonspecific signs of intestinal obstruction and are not used for specific diagnosis preoperatively.<sup>5</sup> Diagnosis is usually made intraoperatively. Delay in the treatment may cause

development of perforation and spontaneous intestinal fistula.<sup>1</sup> In our patient, the preoperative computed tomography findings were consistent with nonspecific subileus findings.

The management of patients with sclerosing encapsulated peritonitis should be symptomatic. Since it can usually be diagnosed intraoperatively, patients should be treated like a normal obstruction patients preoperatively. In the absence of acute abdomen and radiological findings for perforation oral intake can be terminated, parenteral nutrition can be started and the patient may be relieved by nasogastric drainage.<sup>6</sup> Generally, however, these patients respond to surgical treatment and there are several surgical techniques to choose. One of these methods should be selected after intra-operative diagnosis according to condition of the patient and the level of obstruction. Several alternative surgical

options are available such as peritonectomy + adhesiolysis, resection + anastomosis, resection + anastomosis + stoma and combined therapy.<sup>2</sup> Laparoscopy is limited and is not recommended. The most successful one among these options is reported as peritonectomy + adhesiolysis.<sup>10</sup> Thus, we have applied peritonectomy + adhesiolysis surgery to the patient who had her 4<sup>th</sup> relapse.

As a result, sclerosing encapsulated peritonitis, a rare cause of small bowel obstruction, should be kept in mind in early diagnosis especially in patients getting peritoneal dialysis. It can usually be diagnosed intraoperatively and the recommended treatment, if applicable, is peritonectomy + adhesiolysis.

There is no conflict of interest between authors. No financial support has been received.

## REFERENCES

1. Akbulut S, Yagmur Y, Babur M. Coexistence of abdominal cocoon, intestinal perforation and incarcerated Meckel's diverticulum in an inguinal hernia: a troublesome condition. *World J Gastrointest Surg* 2014;6(3):51-4.
2. Li N, Zhu W, Li Y, Gong J, Gu L, Li M, et al. Surgical treatment and perioperative management of idiopathic abdominal cocoon: single-center review of 65 cases. *World J Surg* 2014;38(7):1860-7.
3. Xu P, Chen LH, Li YM. Idiopathic sclerosing encapsulating peritonitis (or abdominal cocoon): a report of 5 cases. *World J Gastroenterol* 2007;13(26):3649-51.
4. Solak A, Solak I. Abdominal cocoon syndrome: preoperative diagnostic criteria, good clinical outcome with medical treatment and review of the literature. *Turk J Gastroenterol* 2012;23(6):776-9.
5. Choi JH, Kim JH, Kim JJ, Jin SY, Choi DL. Large bowel obstruction caused by sclerosing peritonitis: contrast-enhanced CT findings. *Br J Radiol* 2004;77:344-6.
6. Habib AM, Preston E, Davenport A. Risk factors for developing encapsulating peritoneal sclerosis in the icodextrin era of peritoneal dialysis prescription. *Nephrol Dial Transplant* 2010;25(5):1633-8.
7. Menassa-Moussa L, Bleibel L, Sader-Ghorra C, Smayra T, Aoun NJ. MRI findings in intestinal cocoon. *AJR Am J Roentgenol* 2006;186(3):905-6.
8. Stuart S, Booth TC, Cash CJC, Hameeduddin A, Goode JA, Harvey C, et al. Complications of continuous ambulatory peritoneal dialysis. *RadioGraphics* 2009;29(2):441-60.
9. Kawanishi H, Moriishi M. Encapsulating peritoneal sclerosis: prevention and treatment. *Perit Dial Int* 2007;27(Suppl 2):S289-92.
10. Yavuz R, Akbulut S, Babur M, Demircan F. Intestinal obstruction due to idiopathic sclerosing encapsulating peritonitis: a case report. *Iran Red Crescent Med J* 2015;17(5): e21934.