

Treatment of the fistula tract with laser ablation in high anal fistulas

Erkan Karacan¹, Eyüp Murat Yılmaz²

¹General Surgery Department, Karabük University Research and Training Hospital, Karabük, Turkey

²General Surgery Department, Aydın General Surgery Clinic, Aydın, Turkey

Received: 2022-09-17.

Accepted: 2022-11-04



This work is licensed under a
Creative Commons Attribution 4.0
International License

J Clin Med Kaz 2022; 19(6):43-45

Corresponding author:

Eyüp Murat Yılmaz.

E-mail: drmyilmaz80@gmail.com;

ORCID: 0000-0002-0808-5067

Abstract

Aim and introduction: Considering the recurrence and fecal incontinence rates in high anal fistulas, surgical treatment of anal fistulas is a challenging process, although many treatments have been defined today. The aim of our study is to evaluate the long-term results of laser ablation of the fistula tract in high anal fistulas.

Material and methods: The files of patients who underwent laser ablation of the fistula tract due to high anal fistula between June 2020 and January 2022 were evaluated retrospectively. Moreover, their postoperative complications, preoperative and postoperative Cleveland fecal incontinence scores (CCFFSI score), postoperative first day and first-week visual analog scale (VAS) scores, follow-up times, and recurrence rates were analyzed.

Results: 26 patients were included in the study. The mean follow-up period was 39.88 ± 14.34 weeks, and the postoperative first and 7th day VAS scores were 4.61 ± 1.41 and 0.8 ± 1.02 , respectively. Preoperative and postoperative CCFI scores were calculated as 1.8 ± 1.41 , 1.65 ± 1.32 , respectively. Recurrence was observed in 7 patients postoperatively. Postoperative anal abscess developed in 1 patient.

Conclusion: Although laser ablation of the fistula tract can be safely performed as a technique that does not affect incontinence, recurrence rates should also be considered. Furthermore, more extensive randomized prospective studies on this technique should be performed.

Key words: high anal fistula, laser ablation of fistula tract, laser

Introduction

Anal fistulas occur as a result of chronic infection of cryptoglandular structures in the anal canal and almost always require surgical treatment [1]. Though many surgical techniques are defined for the treatment of anal fistula today, when long-term data are evaluated, there is no single gold standard treatment method [2]. In terms of sphincter-preserving techniques, rectal mucosal advancement flaps, LIFT (ligation of the intersphincteric fistula tract), VAAFT (video-assisted anal fistula treatment) and laser ablation procedures (LAFT) are some of these methods [3-6].

According to Milligan and Morgan, anal fistulas are divided into high and low according to the closure rate of the puborectal muscle and external sphincter [7].

In our study, we aimed to evaluate the results of laser ablation treatment applied as a new technique in patients with high anal fistula.

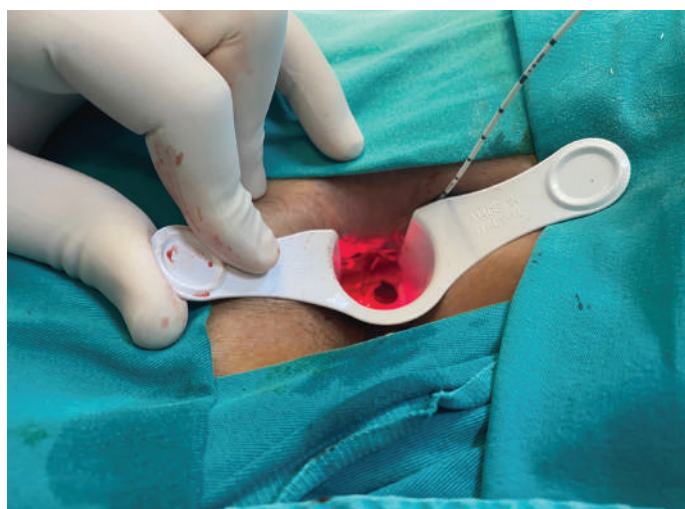
Material and methods

The files of patients who underwent laser ablation of the fistula tract due to high anal fistula between June 2020 and January 2022 in Aydın Surgery Clinic at Turkey, Aydın were evaluated retrospectively. Moreover, their postoperative complications, preoperative and postoperative Cleveland fecal incontinence scores (CCFFSI score), postoperative first day and first-week visual analog scale (VAS) scores, follow-up times, and recurrence rates were analyzed. Patients with a follow-up period of less than 6 months were excluded from the study in order to more clearly evaluate the postoperative recurrences of the patients. Patients with Crohn's disease, cancer patients, patients who developed fistula secondary to trauma, and patients who were treated for anal fistula due to recurrence, and low anal fistula were excluded from the study.

Surgical method

Enema was applied to the patients 2 hours before the operation. Preoperatively, 1 gr ampicillin/sulbactam was administered intravenously. After spinal anesthesia, the patients were prepared in lithotomy or jack knife position according to the location of the external of the fistula. By revealing the external fistula tract, hydrogen peroxide was injected through the external sphincter orifice and the internal sphincter opening was revealed with the help of anal retractor. The fistula tract was determined with a stylet. Following that, the brush stylet fistula tract was debrided. Then, the 1000- μ m-diameter radial laser probe (FiLaC®) was advanced and removed from the internal of the fistula (Figure 1).

Figure 1 - Treatment of the fistula tract with laser ablation in high anal fistulas



According to the size of the 1470 nm 10 watt energy fistula tract, an average of 12-18 shots were made along the fistula tract in total. The external orifice was excised and left open for drainage.

Statistical analysis

For data evaluation, the SPSS 25 (IBM Corp. Released 2017. IBM SPSS Statistics for Windows, Version 25.0. Armonk, NY: IBM Corp.) statistical packaged program was used. The variables were stated using the mean \pm standard deviation, percentage and frequency values. Kolmogorov Smirnov test was performed to evaluate the homogeneity of the data. In the analysis of data, Mann-Whitney U test were used for the comparison of CCFFSI and VAS scores. $P < 0.05$ was considered statistically significant.

Results

A total of 26 patients were included in the study, of which 17 (65.4%) were male and 9 (34.6%) were female. The mean age of the patients was calculated as 40.2 ± 11.2 . High fistulas were included in the study and 18 (69.2%) were transsphincteric and 8 (30.8%) were extrasphincteric. The follow-up period of the patients was calculated as 39.88 ± 14.34 weeks. Recurrence was detected in 7 (26.9%) of the patients included in the study. When the VAS scores were examined, it was 4.61 ± 1.41 on the postoperative 1st day and 0.8 ± 1.02 on the postoperative 7th day ($p < 0.001$) (Table 1). When considered as a complication, perianal abscess developed in one patient on the postoperative 4th day (3.8%). Globe vesicale developed in one patient one postoperative first day (3.8%) (Table 2).

Table 1 Score and general definitions

| | | |
|-----------------------------------|----------------------------|---------------------------|
| Age | 40.2 ± 11.2 | |
| CCFFSI score preoperative | 1.8 ± 1.41 | |
| CCFFSI score postoperative 1.week | 1.65 ± 1.32 | |
| Vas score postoperative 1.day | 4.61 ± 1.41 | |
| Vas score post op 7.day | 0.8 ± 1.02 | |
| Follow-up time | $39.88\pm 14.34(24-75)$ | |
| Recurrence | 7(26.9%) | |
| Gender | 17(65.4%) | |
| man | 9(34.6%) | woman |
| Fistula type | 18(69.2%) transsphincteric | 8(30.8%) extrasphincteric |

Table 2 Complications

| | |
|------------------|----------|
| Perianal abscess | 1 (3,8%) |
| Globe vesicale | 1 (3,8%) |

Table 3 Preoperative and postoperative scores

| | | |
|-----------------------------------------|-----------------------------------------|-------------|
| Preoperative CCFI score 1.8 ± 1.41 | Postoperative CCFI score 1.65 ± 1.32 | $p=0.1$ |
| Postoperative 1. day VAS 4.61 ± 1.41 | Postoperative 7. day VAS 0.8 ± 1.02 | $p < 0.001$ |

Considering the CCFFSI scoring, while the preoperative value was 1.8 ± 1.41 , it was calculated as 1.65 ± 1.32 at postoperative 1st week ($p=0.1$) (Table 3).

Discussion

Although many sphincter sparing techniques have been described for high anal fistulas, none of these techniques have taken their place in the literature as the gold standard treatment. The fibrin glue technique, which is one of these techniques, recurrence rates were found to be high [8,9]. In a meta-analysis study conducted on another technique, the LIFT technique, the success rates were reported to be around 76%, and its protective effect on incontinence was stated to be present [10]. In a another study about modified LIFT technique Celayir et al [11] reported success rate about 87.5%. In a study on rectal mucosal advancement flaps, the recurrence rate was reported as 23% [12]. In the literature, factors affecting recurrence in anal fistula have been reported as recurrent anal fistulas, diabetes, smoking, and immunosuppressive diseases [13]. Since our study was retrospective, the risk factors of the patients could not be evaluated. Although there are studies showing recurrence rates in the range of 18-75% after the LAFT technique, recurrence was found in 7 patients in our study, and our recurrence rate was found to be 26.9% [14,15].

Anal fistula poses a serious problem after surgery, particularly after surgery for high fistulas. Ege et al. found no significant difference between preoperative and postoperative incontinence scores after hybrid seton surgery in high anal fistulas [16]. There are a few studies in the literature that evaluate with the incontinence scoring system after the LAFT technique. In a study on the LAFT technique, Giamundo et al [17] found no significant difference between preoperative and postoperative CCFFSI scores. Similarly in our study, no significant difference was found between the preoperative and postoperative 1st week CCFFSI scores. In another study Wilhelm et al [18] reported that

no continence developed in their patients after LAFT. Hence, it can be said that the LAFT technique is a reliable technique for incontinence.

Patient comfort and quality of life are important after surgery in anorectal diseases. There are many studies available to detect this aspect. In particular, pain can be encountered as a distressing symptom postoperatively after fistula surgeries. In a study conducted by Giamundo et al [17] on the LAFT technique, the mean VAS values were found to be 4 in the VAS surveys to evaluate the preoperative and postoperative pain status, and no change was detected [17]. In our study, on the other hand, while VAS values were found to be 4.61 ± 1.41 on postoperative 1st day, on postoperative 7th day it was found to be 0.8 ± 1.02 and a significant decrease in pain level was detected. In terms of postoperative pain, LAFT can be considered as a comfortable method. For more detailed post-operative comfort, quality of life questionnaires such as SF-36 are required. However, as our study was a retrospective study, a questionnaire could not be applied to the patients.

Conclusion

Although the LAFT technique is not the gold standard treatment for high anal fistulas, it can be considered as a method

that can be preferred in terms of preserving sphincter functions and postoperative pain comfort; however, surgical recurrence rates should also be considered. We believe that prospective studies with other techniques are needed to access more detailed information.

Study limitations: The main limitations of this study are that it is retrospective, and low number of patients.

Ethics Committee Approval: The study protocol was approved by Institutional Research Ethic committee.

Informed Consent: All patients were informed about the procedure, and certificate of consent was taken for every patient.

Disclosures: There is no conflict of interest for all authors.

Acknowledgements: None.

Funding: None.

References

1. Emile SH, Elfeki H, Thabet W, Sakr A, Magdy A, El-Hamed TMA, et al. Predictive factors for recurrence of high transsphincteric anal fistula after placement of seton. *J Surg Res*. 2017;213:261-268. <https://doi.org/10.1016/j.jss.2017.02.053>
2. Adegbola SO, Sahnun K, Pellino G, Tozer PJ, Hart A, Phillips RKS, et al. Short-term efficacy and safety of three novel sphincter-sparing techniques for anal fistula: a systematic review. *Tech Coloproctol*. 2017;21(10):775–782. <https://doi.org/10.1007/s10151-017-1699-4>
3. Balciscueta Z, Uribe N, Balciscueta I, Andreu-Ballester JC, García-Granero E. Rectal advancement flap for the treatment of complex cryptoglandular anal fistulas: a systematic review and meta-analysis. *Int J Colorectal Dis*. 2017;32(5):599–609. <https://doi.org/10.1007/s00384-017-2779-7>
4. Hong KD, Kang S, Kalaskar S, Wexner SD. Ligation of intersphincteric fistula tract (LIFT) to treat anal fistula: systematic review and meta-analysis. *Tech Coloproctol*. 2014;18:685–691 <https://doi.org/10.1007/s10151-014-1183-3>
5. Meinerio P, Mori L. Video-assisted anal fistula treatment (VAAFT): a novel sphincter-saving procedure for treating complex anal fistulas. *Tech Coloproctol*. 2011;15(4):417–422. <https://doi.org/10.1007/s10151-011-0769-2>
6. Wilhelm A. A new technique for sphincter-preserving anal fistula repair using a novel radial emitting laser probe. *Tech Coloproctol*. 2011;15(4):445–449. <https://doi.org/10.1007/s10151-011-0726-0>
7. Shirah BH, Shirah HA. The impact of the outcome of treating a high anal fistula by using a cutting seton and staged fistulotomy on Saudi Arabian patients. *Annals of Coloproctology*. 2018;34(5):234-240. <https://doi.org/10.3393/ac.2018.03.23>
8. Yeung JM, Simpson JA, Tang SW, Armitage NC, Maxwell-Armstrong C. Fibrin glue for the treatment of fistulae in ano—a method worth sticking to? *Colorectal Dis*. 2010;12:363–366. <https://doi.org/10.1111/j.1463-1318.2009.01801.x>
9. Cestaro G, De Rosa M, Gentile M. Treatment of fistula in ano with fibrin glue: preliminary results from a prospective study. *Miner Chir*. 2014;69:225–228
10. Emile SH, Khan SM, Adejumo A, Koroye O. Ligation of intersphincteric fistula tract (LIFT) in treatment of anal fistula: an updated systematic review, meta-analysis, and meta-regression of the predictors of failure. *Surgery*. 2020;167(2):484–492. <https://doi.org/10.1016/j.surg.2019.09.012>
11. Celayir MF, Bozkurt E, Aygun N, Mihmanli M. Complex anal fistula: long-term results of modified ligation of intersphincteric fistula tract=LIFT. *The Medical Bulletin of Sisli Etfal Hospital*. 2020;54(3): 297-301 <https://doi.org/10.14744/SEMB.2020.89106>
12. Kılıç A, Tilev SM, Başak F, Şişik A. Rectal flap experience in high transsphincteric cryptoglandular anal fistula. *J Surg Med*. 2019;3(10):746-748. <https://doi.org/10.28982/josam.636918>
13. Bakhtawar N, Usman M. Factors increasing the risk of recurrence in fistula-in-ano. *Cureus*. 2019;11:4200. <https://doi.org/10.7759/cureus.420010.1016/j.surg.2019.09.012>
14. Stijns J, Van Loon YT, Clermonts S, Göttingen KW, Wasowicz DK, Zimmerman DDE. Implementation of laser ablation of fistula tract (LAFT) for perianal fistulas: do the results warrant continued application of this technique? *Tech Coloproctol*. 2019;23:1127–1132. <https://doi.org/10.1007/s10151-019-02112-9>
15. Öztürk E, Gülcü B. Laser ablation of fistula tract: a sphincter-preserving method for treating fistula-in-ano. *Dis Colon Rectum*. 2014;57:360–364. <https://doi.org/10.1097/DCR.0000000000000067>
16. Ege B, Leventoğlu S, Menten BB, Yılmaz U, Oner AY. Hybrid seton for the treatment of high anal fistulas: results of 128 consecutive patients. *Tech Coloproctol*. 2014;18:187–193. <https://doi.org/10.1007/s10151-013-1021-z>
17. Giamundo P, Geraci M, Tibaldi L, Valente M. Closure of fistula-in-ano with laser-FiLaCTM™: an effective novel sphincter-saving procedure for complex disease. *Colorectal Dis*. 2014;16:110–115. <https://doi.org/10.1111/codi.12440>
18. Wilhelm A, Fiebig A, Krawczak M. Five years of experience with the FiLaCTM laser for fistula-in-ano management: long-term follow-up from a single institution. *Tech Coloproctol*. 2017;21:269–276. <https://doi.org/10.1007/s10151-017-1599-7>